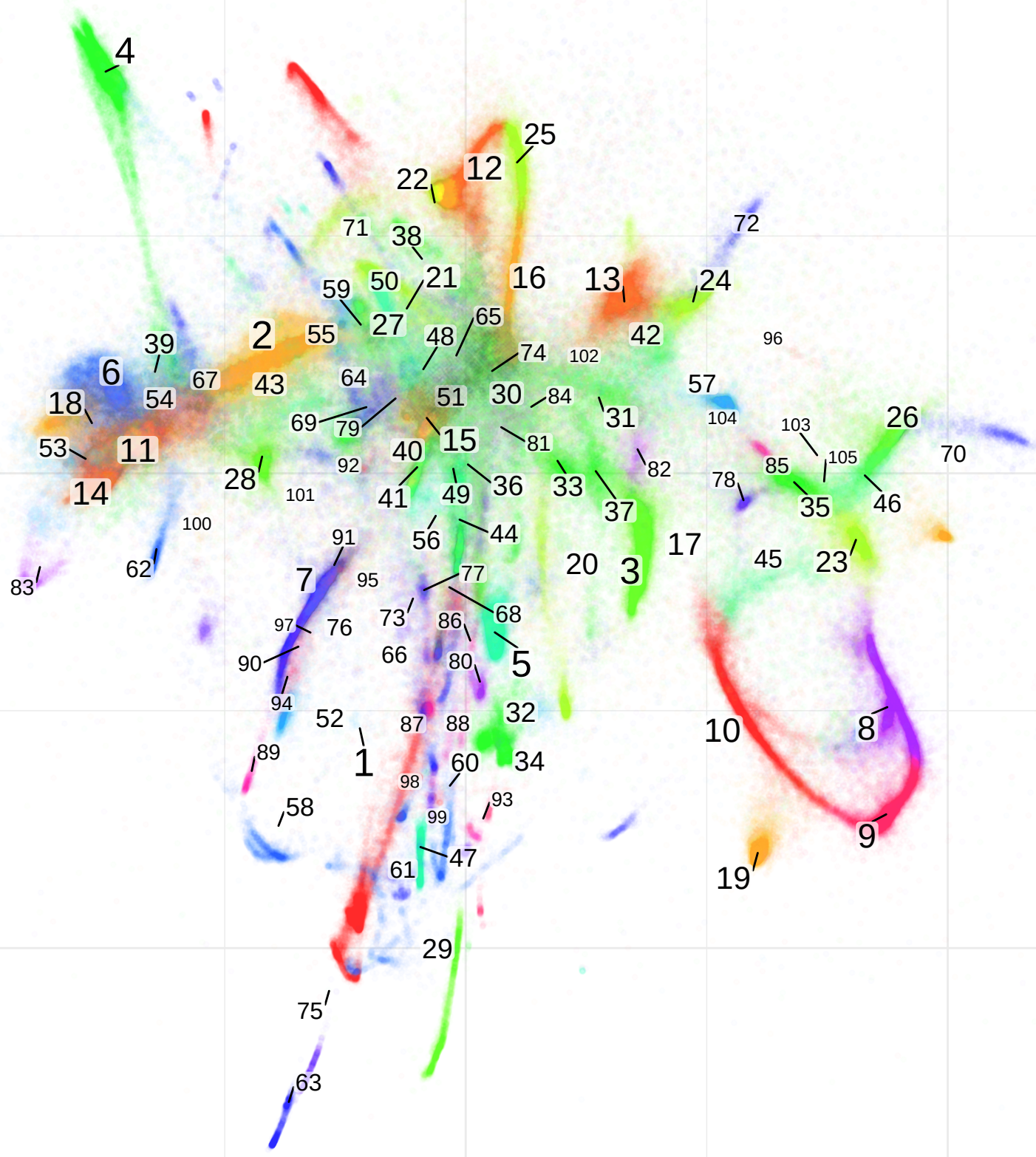
4
25
12
22
71
38
72
21
16
13
24
59
50
27
65
2
55
48
42
96
39
74
102
6
67
43
64
57
18
54
51
30
84
31
104
26
69
79
103
53
11
40
15
81
105
70
92
82
85
28
78
14
101
41
49
36
33
37
35
46
100
91
56
44
17
45
23
83
62
7
95
77
20
3
73
86
68
97
76
66
80
5
90
94
52
87
88
32
10
8
89
1
60
34
98
58
93
99
9
47
61
19
29
75
63

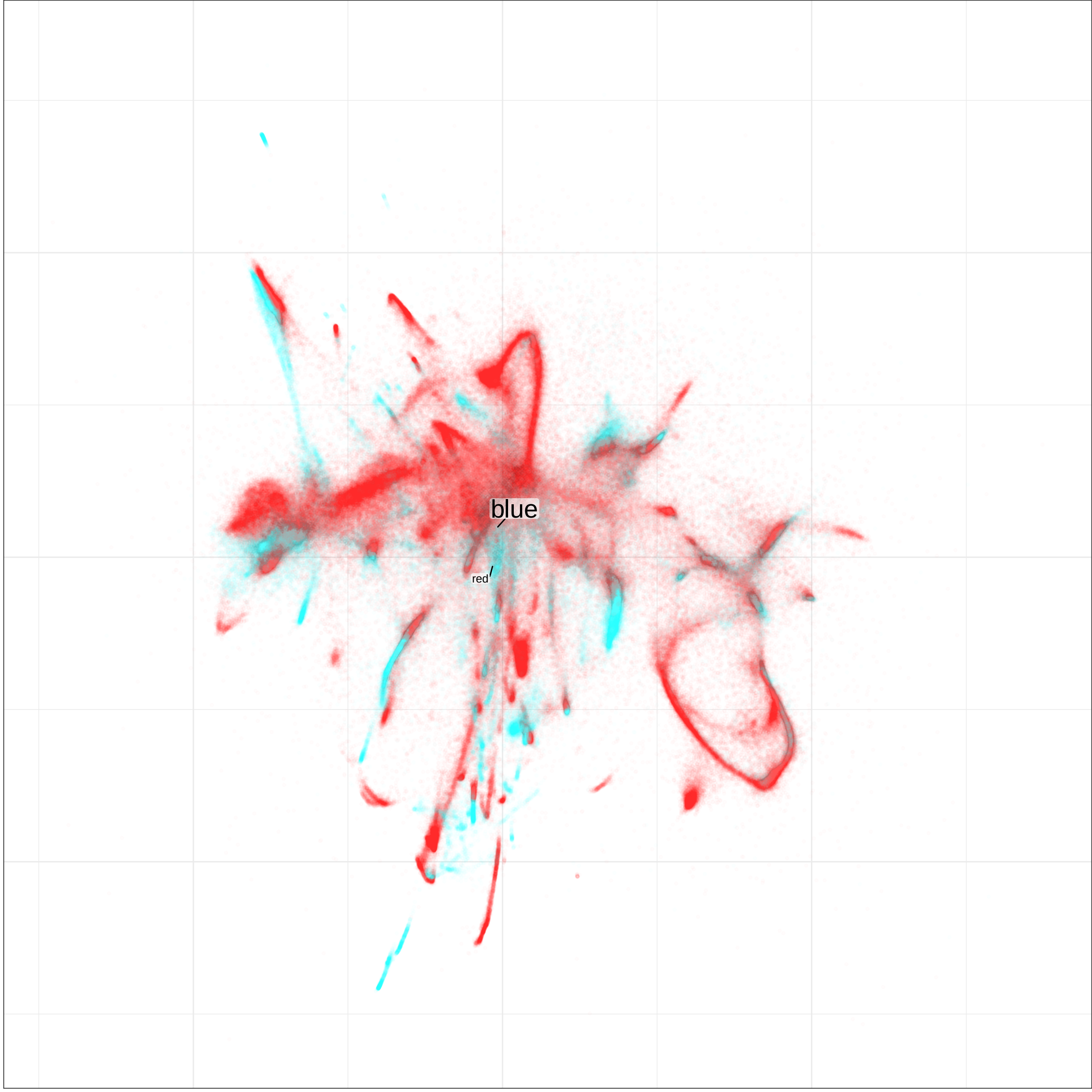
blue
red

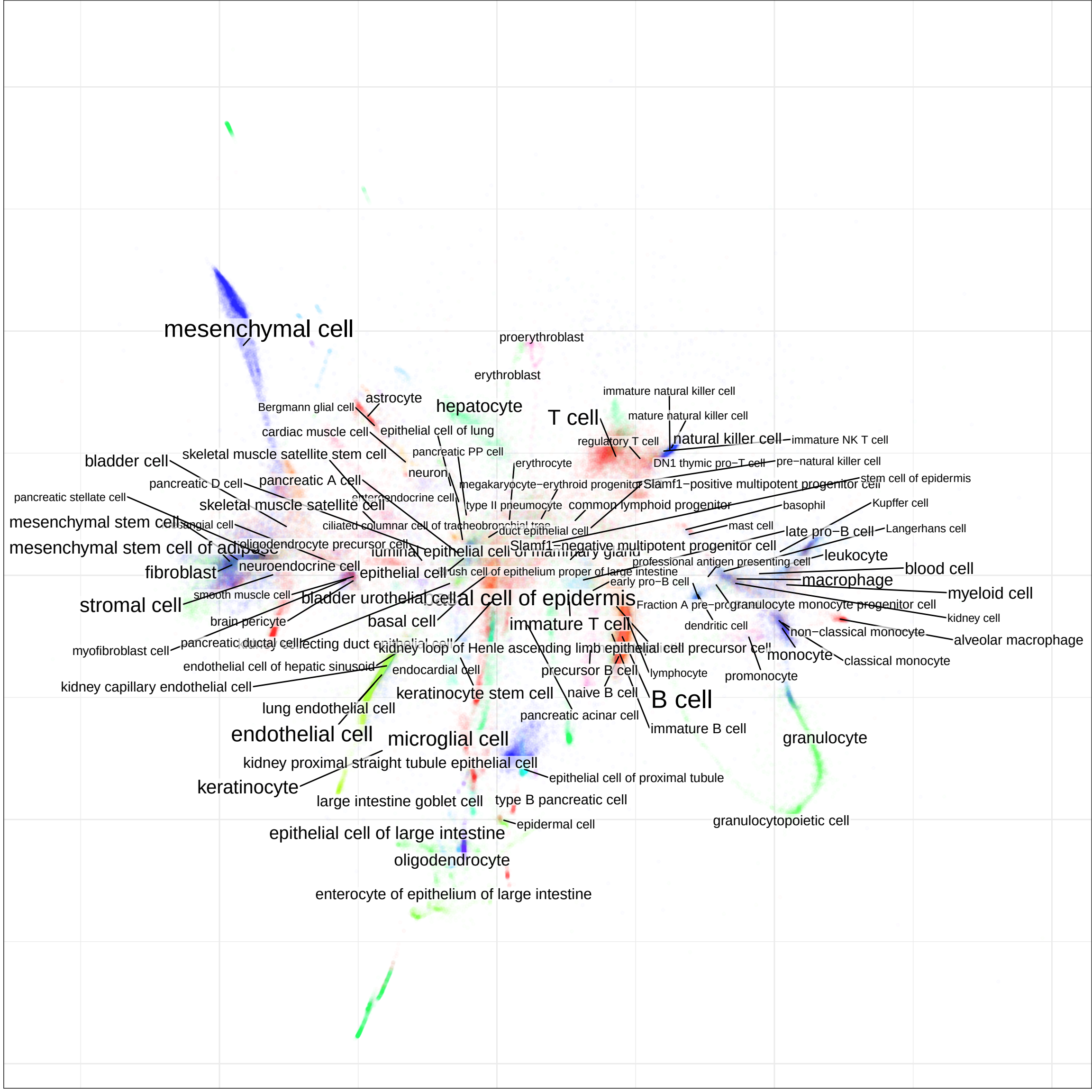
mesenchymal cell
proerythroblast
erythroblast
immature natural killer cell
astrocyte
hepatocyte
T cell
Bergmann glial cell
mature natural killer cell
cardiac muscle cell
epithelial cell of lung
regulatory T cell
natural killer cell
immature NK T cell
skeletal muscle satellite stem cell
pancreatic PP cell
bladder cell
erythrocyte
DN1 thymic pro−T cell
pre−natural killer cell
neuron
pancreatic D cell
pancreatic A cell
megakaryocyte−erythroid progenitor
Slamf1−positive multipotent progenitor cell
stem cell of epidermis
pancreatic stellate cell
enteroendocrine cell
skeletal muscle satellite cell
type II pneumocyte
common lymphoid progenitor
basophil
Kupffer cell
mesenchymal stem cell
mesangial cell
ciliated columnar cell of tracheobronchial trac
duct epithelial cell
mast cell
late pro−B cell
Langerhans cell
mesenchymal stem cell of adipose
oligodendrocyte precursor cell
luminal epithelial cell of mammary gland
Slamf1−negative multipotent progenitor cell
professional antigen presenting cell
leukocyte
fibroblast
neuroendocrine cell
epithelial cell
lush cell of epithelium proper of large intestine
blood cell
early pro−B cell
macrophage
smooth muscle cell
myeloid cell
stromal cell
bladder urothelial cell
al cell of epidermis
Fraction A pre−pro
granulocyte monocyte progenitor cell
kidney cell
brain pericyte
basal cell
immature T cell
dendritic cell
non−classical monocyte
alveolar macrophage
myofibroblast cell
pancreatic ductal cell
lecting duct epithelial cell
kidney loop of Henle ascending limb epithelial cell
precursor cell
monocyte
classical monocyte
endothelial cell of hepatic sinusoid
endocardial cell
precursor B cell
lymphocyte
promonocyte
kidney capillary endothelial cell
keratinocyte stem cell
naive B cell
B cell
lung endothelial cell
pancreatic acinar cell
immature B cell
endothelial cell
microglial cell
granulocyte
kidney proximal straight tubule epithelial cell
epithelial cell of proximal tubule
keratinocyte
large intestine goblet cell
type B pancreatic cell
epidermal cell
granulocytopoietic cell
epithelial cell of large intestine
oligodendrocyte
enterocyte of epithelium of large intestine

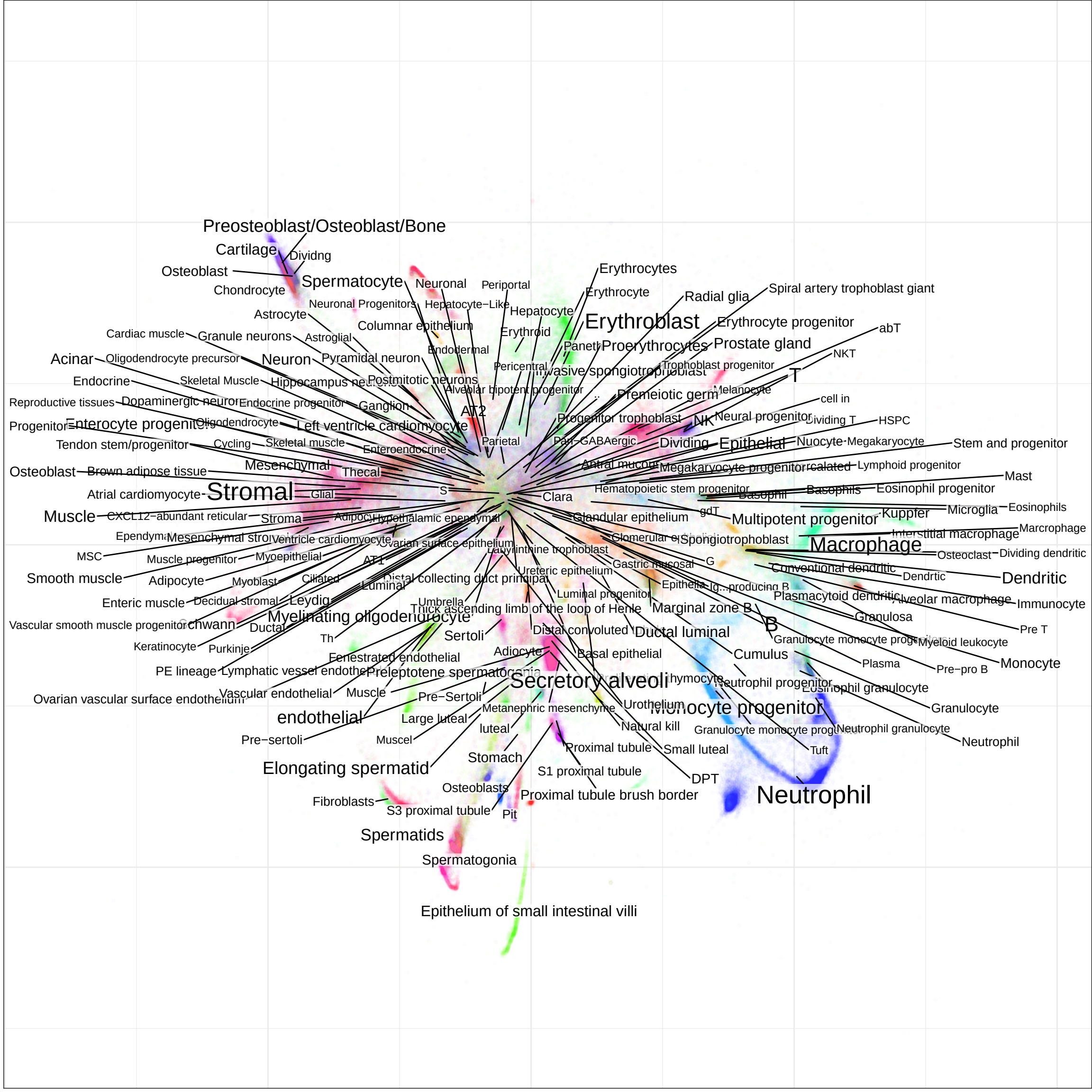
Preosteoblast/Osteoblast/Bone
Cartilage
Dividng
Osteoblast
Spermatocyte
Chondrocyte
Neuronal
Periportal
Erythrocytes
Erythrocyte
Radial glia
Spiral artery trophoblast giant
Neuronal Progenitors
Hepatocyte−Like
Hepatocyte
Erythroblast
Erythrocyte progenitor
abT
Astrocyte
Columnar epithelium
Erythroid
Cardiac muscle
Granule neurons
Astroglial
Paneth
Proerythrocytes
Prostate gland
NKT
Endodermal
Acinar
Oligodendrocyte precursor
Neuron
Pyramidal neuron
Pericentral
Invasive spongiotrophoblast
Trophoblast progenitor
T
Endocrine
Skeletal Muscle
Hippocampus neurons
Postmitotic neurons
Alveolar bipotent progenitor
Premeiotic germ
Melanocyte
Reproductive tissues
Dopaminergic neuron
Endocrine progenitor
Ganglion
AT2
cell in
Progenitor
Enterocyte progenitor
Oligodendrocyte
Left ventricle cardiomyocyte
Progenitor trophoblast
NK
Neural progenitor
Dividing T
HSPC
Tendon stem/progenitor
Cycling
Skeletal muscle
Enteroendocrine
Parietal
Pan−GABAergic
Dividing
Epithelial
Nuocyte
Megakaryocyte
Stem and progenitor
Osteoblast
Brown adipose tissue
Mesenchymal
Thecal
Antral mucous
Megakaryocyte progenitor
calated
Lymphoid progenitor
Mast
Atrial cardiomyocyte
Stromal
Glial
S
Clara
Hematopoietic stem progenitor
Basophil
Basophils
Eosinophil progenitor
Muscle
CXCL12−abundant reticular
Stroma
Adipocyte
Hypothalamic ependymal
Glandular epithelium
gdT
Multipotent progenitor
Kupffer
Microglia
Eosinophils
Ependyma
Mesenchymal stromal
Ventricle cardiomyocyte
Glomerular epithelial
Spongiotrophoblast
Interstitial macrophage
Marcrophage
Ovarian surface epithelium
Macrophage
MSC
Muscle progenitor
Myoepithelial
Labyrinthine trophoblast
Osteoclast
Dividing dendritic
AT1
Gastric mucosal
G
Conventional dendritic
Smooth muscle
Adipocyte
Myoblast
Ciliated
Ureteric epithelium
Dendrtic
Dendritic
Distal collecting duct principal
Luminal
Epithelial
Ig...producing B
Luminal progenitor
Plasmacytoid dendritic
Alveolar macrophage
Immunocyte
Enteric muscle
Decidual stromal
Leydig
Umbrella
Thick ascending limb of the loop of Henle
Marginal zone B
Granulosa
Vascular smooth muscle progenitor
Schwann
Ductal
Myelinating oligodendrocyte
Pre T
Th
Sertoli
Distal convoluted
Ductal luminal
B
Granulocyte monocyte progenitor
Myeloid leukocyte
Keratinocyte
Purkinje
Adiocyte
Basal epithelial
Cumulus
Monocyte
Fenestrated endothelial
Plasma
Pre−pro B
PE lineage
Lymphatic vessel endothelial
Preleptotene spermatocyte
Secretory alveoli
Thymocyte
Neutrophil progenitor
Eosinophil granulocyte
Ovarian vascular surface endothelium
Vascular endothelial
Muscle
Pre−Sertoli
Urothelium
Granulocyte
endothelial
Large luteal
Metanephric mesenchyme
Monocyte progenitor
luteal
Natural kill
Granulocyte monocyte progenitor
Neutrophil granulocyte
Pre−sertoli
Muscel
Proximal tubule
Small luteal
Tuft
Neutrophil
Stomach
Elongating spermatid
S1 proximal tubule
DPT
Osteoblasts
Proximal tubule brush border
Neutrophil
Fibroblasts
S3 proximal tubule
Pit
Spermatids
Spermatogonia
Epithelium of small intestinal villi