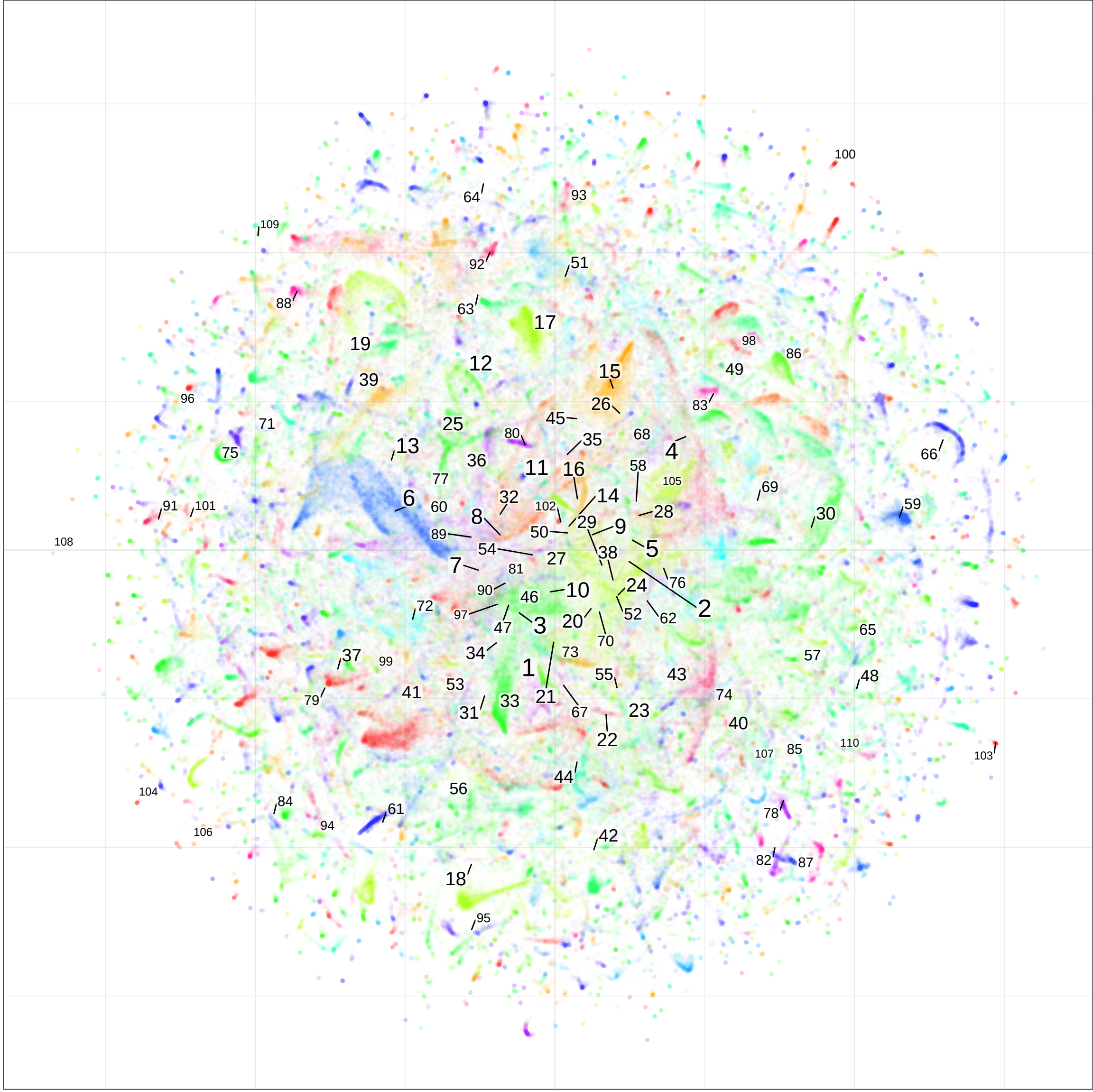
100
64
93
109
92
51
88
63
17
19
98
86
12
15
49
39
96
26
83
71
25
45
80
35
68
4
66
75
13
36
11
16
58
77
105
69
6
32
14
91
101
60
102
28
30
59
8
29
9
108
89
50
5
54
27
38
7
81
76
90
24
10
46
2
72
97
52
62
47
3
20
65
70
37
99
34
73
57
1
55
43
48
53
41
79
33
21
74
31
67
23
40
22
110
107
85
103
44
104
56
84
61
78
94
106
42
82
87
18
95

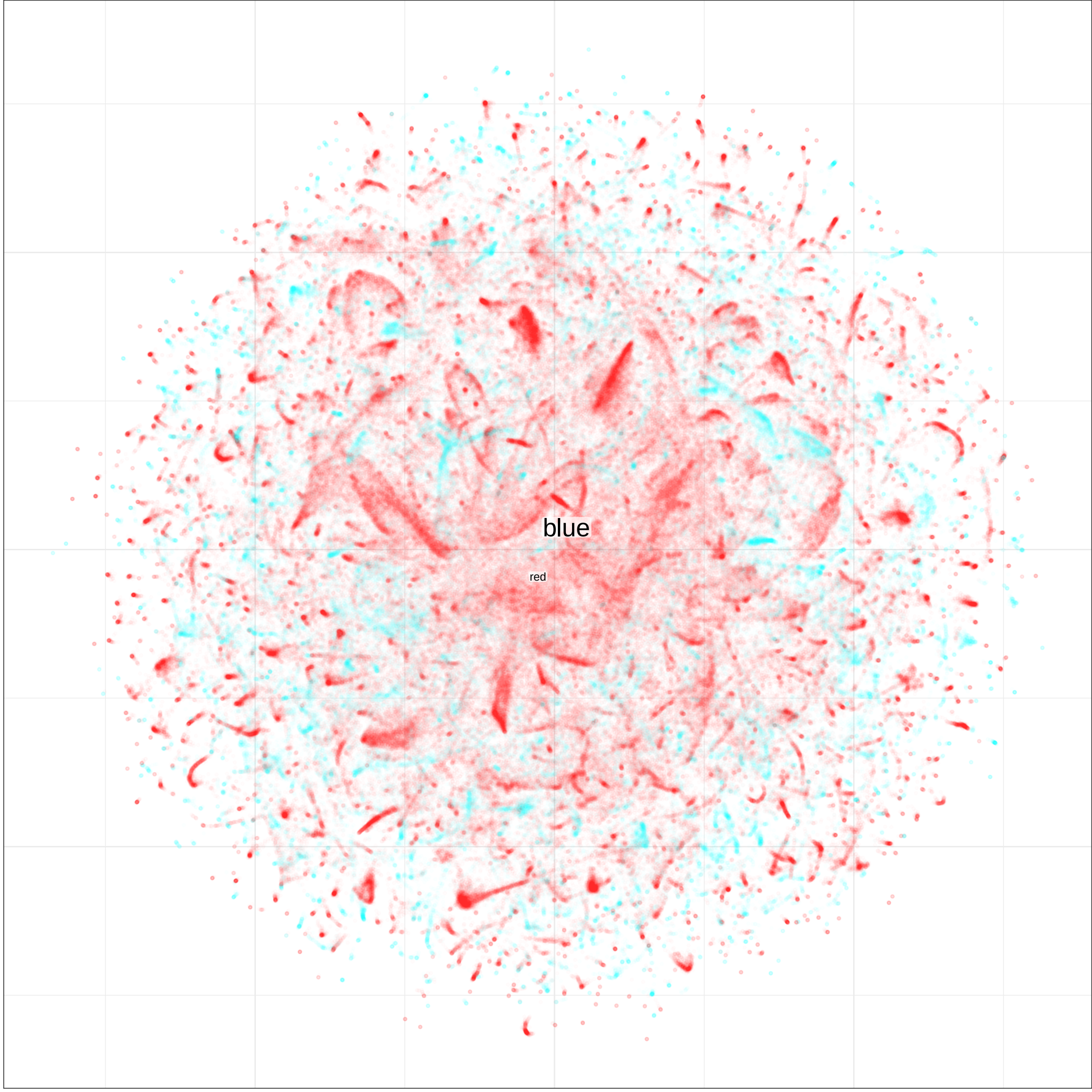
blue
red

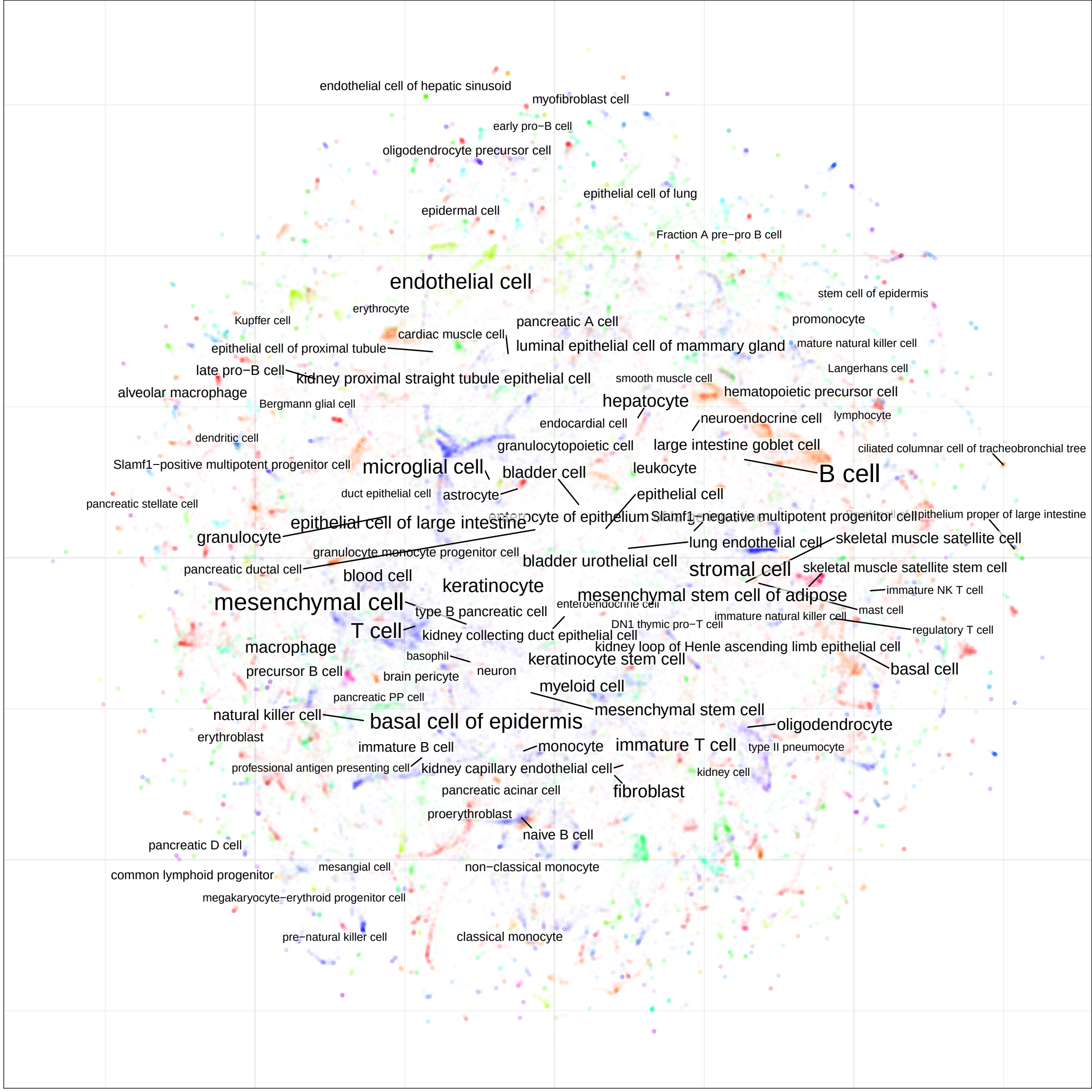
endothelial cell of hepatic sinusoid
myofibroblast cell
early pro−B cell
oligodendrocyte precursor cell
epithelial cell of lung
epidermal cell
Fraction A pre−pro B cell
endothelial cell
stem cell of epidermis
erythrocyte
Kupffer cell
pancreatic A cell
promonocyte
cardiac muscle cell
epithelial cell of proximal tubule
luminal epithelial cell of mammary gland
mature natural killer cell
late pro−B cell
Langerhans cell
kidney proximal straight tubule epithelial cell
smooth muscle cell
alveolar macrophage
hematopoietic precursor cell
Bergmann glial cell
hepatocyte
endocardial cell
neuroendocrine cell
lymphocyte
dendritic cell
granulocytopoietic cell
large intestine goblet cell
ciliated columnar cell of tracheobronchial tree
Slamf1−positive multipotent progenitor cell
microglial cell
bladder cell
leukocyte
B cell
duct epithelial cell
astrocyte
epithelial cell
pancreatic stellate cell
enterocyte of epithelium
Slamf1−negative multipotent progenitor cell
epithelium proper of large intestine
epithelial cell of large intestine
granulocyte
lung endothelial cell
skeletal muscle satellite cell
granulocyte monocyte progenitor cell
bladder urothelial cell
stromal cell
skeletal muscle satellite stem cell
pancreatic ductal cell
blood cell
keratinocyte
immature NK T cell
mesenchymal cell
mesenchymal stem cell of adipose
type B pancreatic cell
enteroendocrine cell
mast cell
T cell
DN1 thymic pro−T cell
immature natural killer cell
kidney collecting duct epithelial cell
regulatory T cell
macrophage
kidney loop of Henle ascending limb epithelial cell
basophil
keratinocyte stem cell
basal cell
precursor B cell
brain pericyte
neuron
myeloid cell
pancreatic PP cell
natural killer cell
mesenchymal stem cell
basal cell of epidermis
oligodendrocyte
erythroblast
immature B cell
monocyte
immature T cell
type II pneumocyte
professional antigen presenting cell
kidney capillary endothelial cell
kidney cell
pancreatic acinar cell
fibroblast
proerythroblast
naive B cell
pancreatic D cell
mesangial cell
non−classical monocyte
common lymphoid progenitor
megakaryocyte−erythroid progenitor cell
pre−natural killer cell
classical monocyte

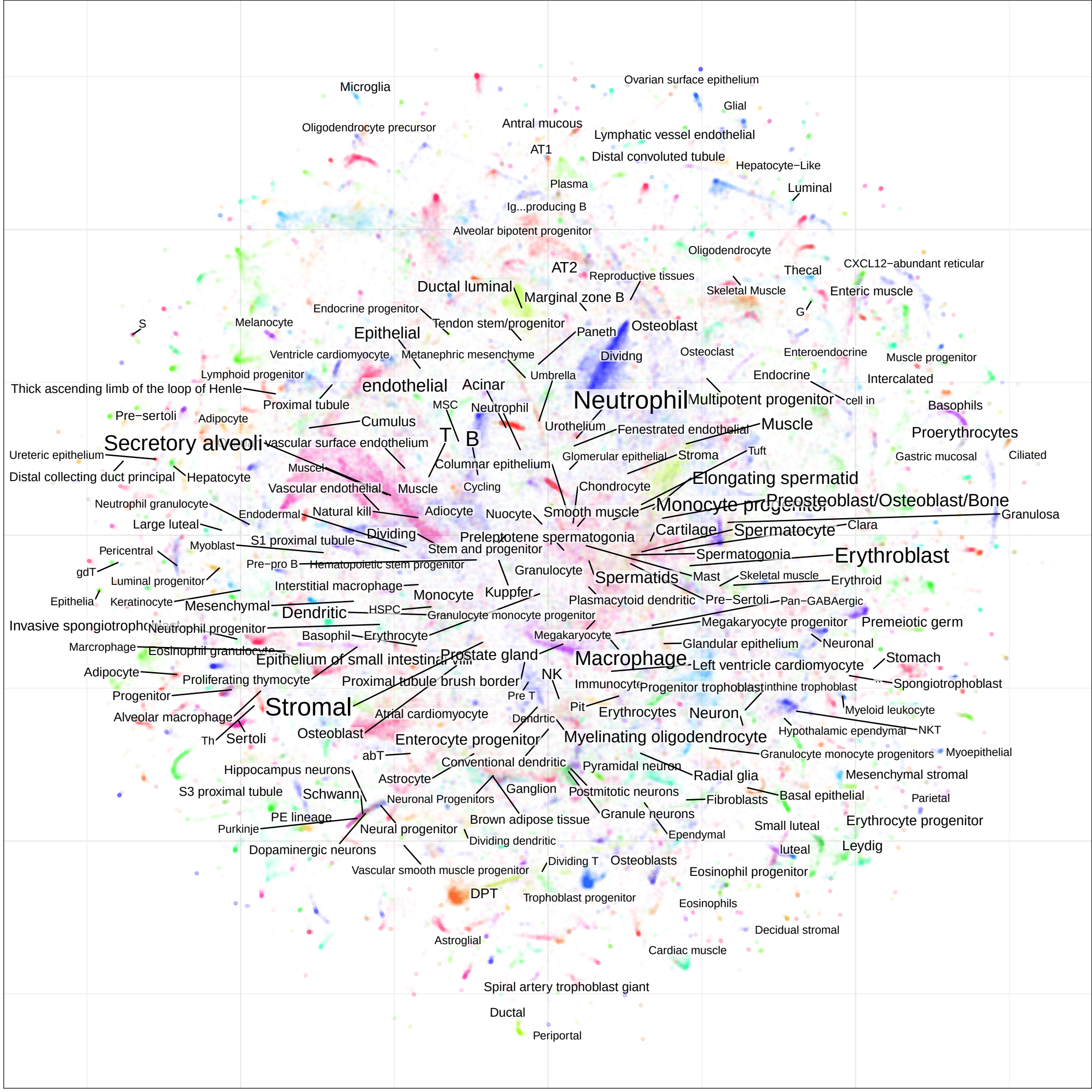
Microglia
Ovarian surface epithelium
Glial
Oligodendrocyte precursor
Antral mucous
Lymphatic vessel endothelial
AT1
Distal convoluted tubule
Hepatocyte−Like
Plasma
Luminal
Ig...producing B
Alveolar bipotent progenitor
Oligodendrocyte
AT2
Reproductive tissues
Thecal
CXCL12−abundant reticular
Ductal luminal
Marginal zone B
Skeletal Muscle
Enteric muscle
Endocrine progenitor
G
S
Melanocyte
Tendon stem/progenitor
Epithelial
Paneth
Osteoblast
Ventricle cardiomyocyte
Metanephric mesenchyme
Dividng
Osteoclast
Enteroendocrine
Muscle progenitor
Lymphoid progenitor
Umbrella
Endocrine
Intercalated
Thick ascending limb of the loop of Henle
endothelial
Acinar
Neutrophil
Multipotent progenitor
cell in
Basophils
Proximal tubule
MSC
Neutrophil
Pre−sertoli
Adipocyte
Cumulus
Urothelium
Fenestrated endothelial
Muscle
Secretory alveoli
T
B
Proerythrocytes
vascular surface endothelium
Ureteric epithelium
Glomerular epithelial
Stroma
Tuft
Gastric mucosal
Ciliated
Columnar epithelium
Distal collecting duct principal
Hepatocyte
Muscel
Elongating spermatid
Vascular endothelial
Muscle
Cycling
Chondrocyte
Monocyte progenitor
Preosteoblast/Osteoblast/Bone
Neutrophil granulocyte
Endodermal
Natural kill
Adiocyte
Nuocyte
Smooth muscle
Granulosa
Large luteal
Cartilage
Spermatocyte
Clara
Dividing
Preleptotene spermatogonia
S1 proximal tubule
Myoblast
Stem and progenitor
Spermatogonia
Erythroblast
Pericentral
Pre−pro B
Hematopoietic stem progenitor
gdT
Granulocyte
Spermatids
Mast
Skeletal muscle
Erythroid
Luminal progenitor
Interstitial macrophage
Monocyte
Kuppfer
Epithelia
Keratinocyte
Mesenchymal
Dendritic
HSPC
Plasmacytoid dendritic
Pre−Sertoli
Pan−GABAergic
Granulocyte monocyte progenitor
Invasive spongiotrophoblast
Neutrophil progenitor
Megakaryocyte progenitor
Premeiotic germ
Basophil
Erythrocyte
Megakaryocyte
Glandular epithelium
Neuronal
Marcrophage
Eosinophil granulocyte
Epithelium of small intestinal villi
Prostate gland
Macrophage
Left ventricle cardiomyocyte
Stomach
Adipocyte
Proliferating thymocyte
Proximal tubule brush border
NK
Immunocyte
Progenitor trophoblast
Intrathine trophoblast
Spongiotrophoblast
Progenitor
Pre T
Pit
Erythrocytes
Neuron
Myeloid leukocyte
Stromal
Alveolar macrophage
Atrial cardiomyocyte
Dendrtic
Hypothalamic ependymal
NKT
Th
Sertoli
Osteoblast
Enterocyte progenitor
Myelinating oligodendrocyte
abT
Granulocyte monocyte progenitors
Myoepithelial
Conventional dendritic
Pyramidal neuron
Hippocampus neurons
Astrocyte
Radial glia
Mesenchymal stromal
S3 proximal tubule
Schwann
Ganglion
Postmitotic neurons
Fibroblasts
Basal epithelial
Parietal
Neuronal Progenitors
PE lineage
Brown adipose tissue
Granule neurons
Erythrocyte progenitor
Purkinje
Neural progenitor
Ependymal
Small luteal
Dividing dendritic
luteal
Leydig
Dopaminergic neurons
Vascular smooth muscle progenitor
Dividing T
Osteoblasts
Eosinophil progenitor
DPT
Trophoblast progenitor
Eosinophils
Decidual stromal
Astroglial
Cardiac muscle
Spiral artery trophoblast giant
Ductal
Periportal