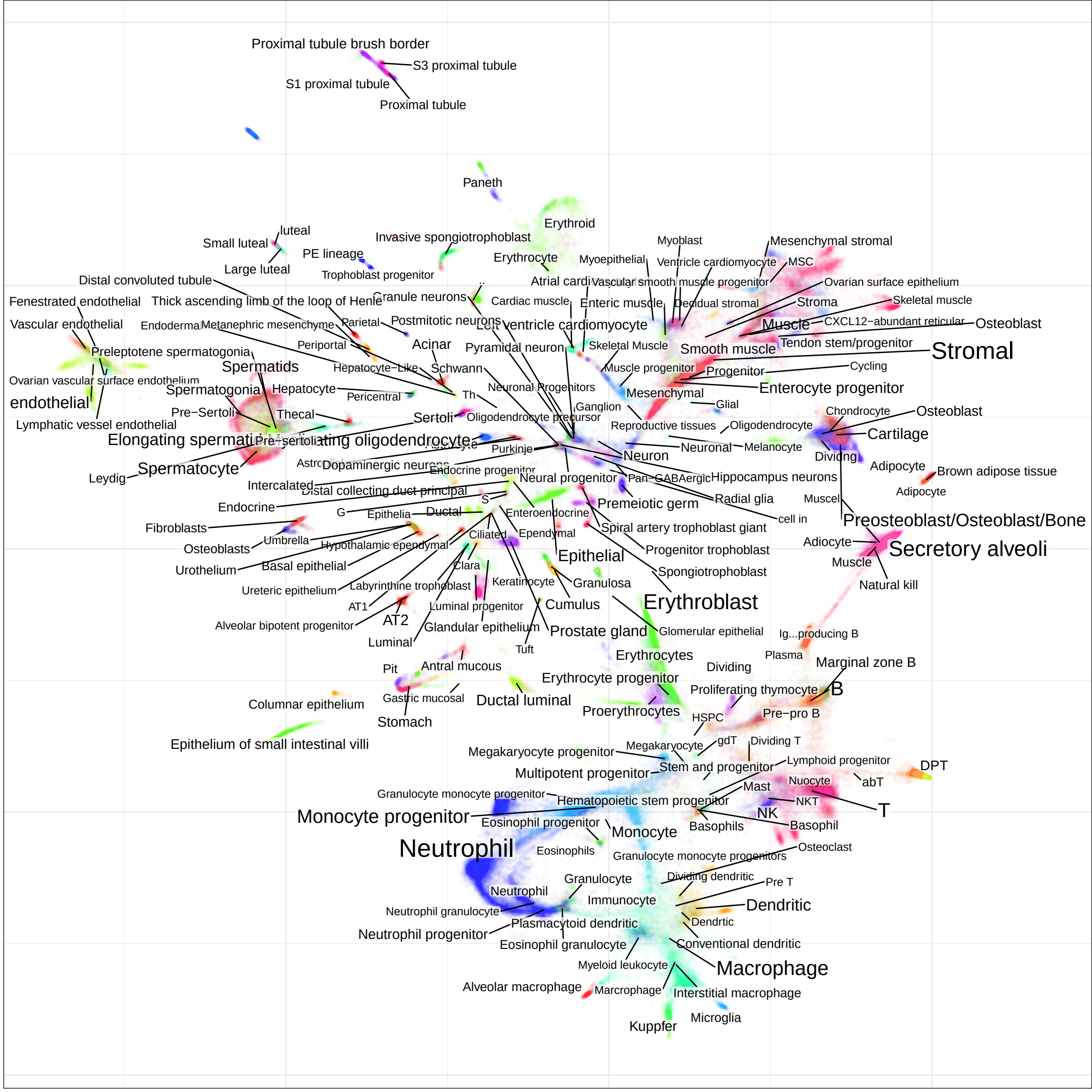
Proximal tubule brush border
S3 proximal tubule
S1 proximal tubule
Proximal tubule
Paneth
Erythroid
luteal
Small luteal
Large luteal
PE lineage
Invasive spongiotrophoblast
Trophoblast progenitor
Erythrocyte
Myoblast
Mesenchymal stromal
Myoepithelial
Ventricle cardiomyocyte
MSC
Distal convoluted tubule
Atrial cardi
Vascular smooth muscle progenitor
Ovarian surface epithelium
Fenestrated endothelial
Thick ascending limb of the loop of Henle
Granule neurons
Cardiac muscle
Enteric muscle
Decidual stromal
Stroma
Skeletal muscle
Vascular endothelial
Endoderma
Metanephric mesenchyme
Parietal
Postmitotic neurons
Left ventricle cardiomyocyte
Muscle
CXCL12−abundant reticular
Osteoblast
Periportal
Acinar
Pyramidal neuron
Skeletal Muscle
Smooth muscle
Tendon stem/progenitor
Stromal
Preleptotene spermatogonia
Spermatids
Hepatocyte−Like
Schwann
Muscle progenitor
Progenitor
Cycling
Ovarian vascular surface endothelium
Spermatogonia
Hepatocyte
Pericentral
Th
Neuronal Progenitors
Mesenchymal
Enterocyte progenitor
endothelial
Pre−Sertoli
Thecal
Sertoli
Oligodendrocyte precursor
Ganglion
Glial
Chondrocyte
Osteoblast
Lymphatic vessel endothelial
Reproductive tissues
Oligodendrocyte
Cartilage
Elongating spermati
Pre−sertoli
ating oligodendrocyte
Purkinje
Neuronal
Melanocyte
Dividing
Neuron
Spermatocyte
Astrocyte
Dopaminergic neurons
Adipocyte
Brown adipose tissue
Leydig
Endocrine progenitor
Neural progenitor
Pan−GABAergic
Hippocampus neurons
Intercalated
Distal collecting duct principal
Radial glia
Adipocyte
Endocrine
S
Premeiotic germ
Muscel
G
Epithelia
Ductal
Enteroendocrine
cell in
Preosteoblast/Osteoblast/Bone
Fibroblasts
Spiral artery trophoblast giant
Umbrella
Ciliated
Ependymal
Adiocyte
Osteoblasts
Hypothalamic ependymal
Progenitor trophoblast
Secretory alveoli
Epithelial
Muscle
Urothelium
Basal epithelial
Clara
Spongiotrophoblast
Natural kill
Keratinocyte
Granulosa
Ureteric epithelium
Labyrinthine trophoblast
Erythroblast
AT1
Luminal progenitor
Cumulus
AT2
Alveolar bipotent progenitor
Glandular epithelium
Prostate gland
Glomerular epithelial
Ig...producing B
Luminal
Tuft
Erythrocytes
Plasma
Marginal zone B
Pit
Antral mucous
Dividing
Erythrocyte progenitor
Proliferating thymocyte
B
Columnar epithelium
Gastric mucosal
Ductal luminal
Proerythrocytes
HSPC
Pre−pro B
Stomach
Epithelium of small intestinal villi
Megakaryocyte
gdT
Dividing T
Megakaryocyte progenitor
Lymphoid progenitor
DPT
Stem and progenitor
Multipotent progenitor
Nuocyte
abT
Mast
Granulocyte monocyte progenitor
Hematopoietic stem progenitor
NKT
T
Monocyte progenitor
NK
Eosinophil progenitor
Basophils
Basophil
Monocyte
Neutrophil
Eosinophils
Osteoclast
Granulocyte monocyte progenitors
Dividing dendritic
Granulocyte
Pre T
Neutrophil
Immunocyte
Dendritic
Neutrophil granulocyte
Plasmacytoid dendritic
Dendrtic
Neutrophil progenitor
Eosinophil granulocyte
Conventional dendritic
Myeloid leukocyte
Macrophage
Alveolar macrophage
Marcrophage
Interstitial macrophage
Microglia
Kuppfer

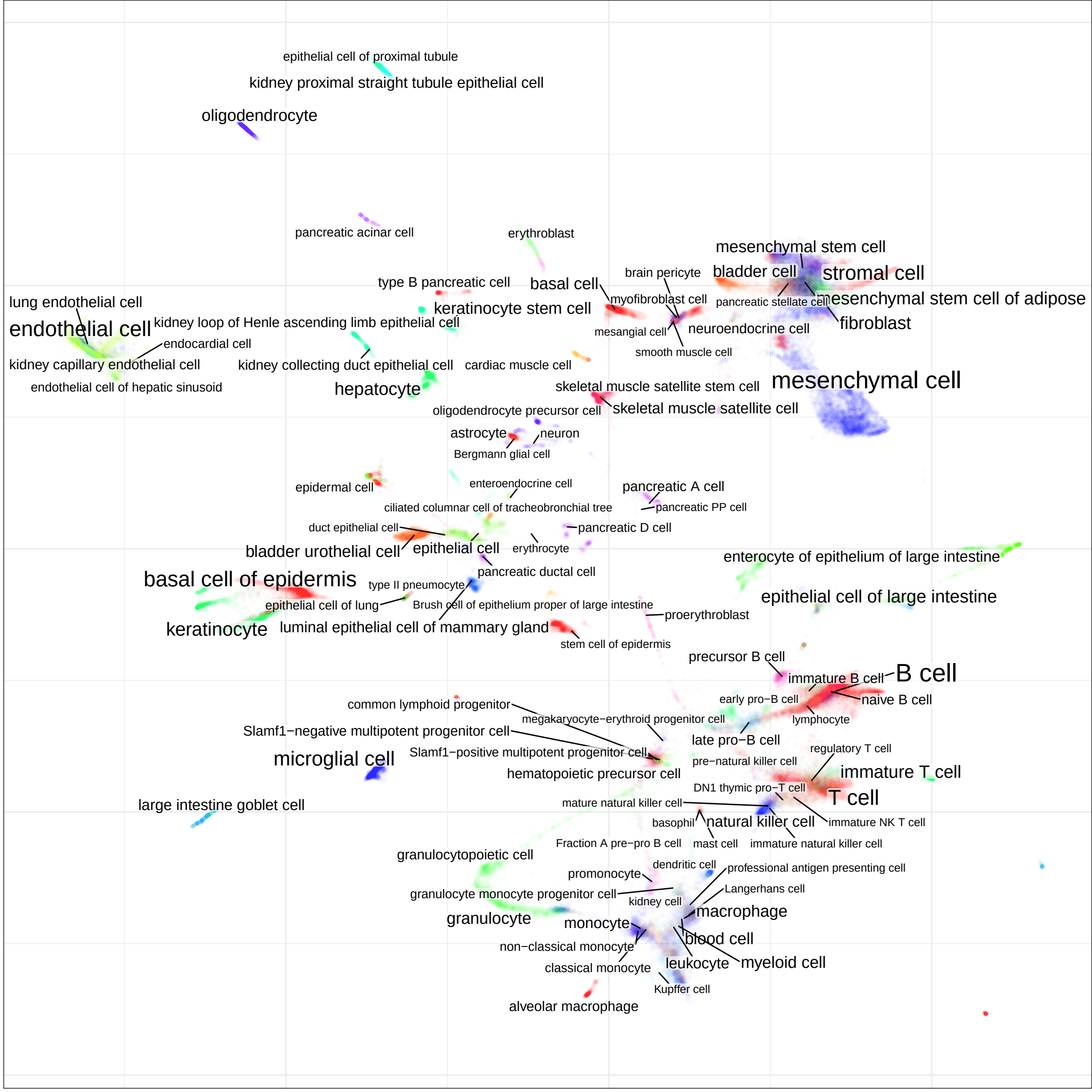
epithelial cell of proximal tubule
kidney proximal straight tubule epithelial cell
oligodendrocyte
pancreatic acinar cell
erythroblast
mesenchymal stem cell
brain pericyte
bladder cell
stromal cell
type B pancreatic cell
basal cell
myofibroblast cell
pancreatic stellate cell
mesenchymal stem cell of adipose
lung endothelial cell
keratinocyte stem cell
fibroblast
endothelial cell
kidney loop of Henle ascending limb epithelial cell
mesangial cell
neuroendocrine cell
endocardial cell
smooth muscle cell
kidney capillary endothelial cell
kidney collecting duct epithelial cell
cardiac muscle cell
endothelial cell of hepatic sinusoid
hepatocyte
skeletal muscle satellite stem cell
mesenchymal cell
oligodendrocyte precursor cell
skeletal muscle satellite cell
astrocyte
neuron
Bergmann glial cell
epidermal cell
enteroendocrine cell
pancreatic A cell
ciliated columnar cell of tracheobronchial tree
pancreatic PP cell
duct epithelial cell
pancreatic D cell
bladder urothelial cell
epithelial cell
erythrocyte
enterocyte of epithelium of large intestine
pancreatic ductal cell
basal cell of epidermis
type II pneumocyte
epithelial cell of large intestine
epithelial cell of lung
Brush cell of epithelium proper of large intestine
proerythroblast
keratinocyte
luminal epithelial cell of mammary gland
stem cell of epidermis
precursor B cell
immature B cell
B cell
early pro−B cell
naive B cell
common lymphoid progenitor
lymphocyte
megakaryocyte−erythroid progenitor cell
Slamf1−negative multipotent progenitor cell
late pro−B cell
regulatory T cell
microglial cell
Slamf1−positive multipotent progenitor cell
pre−natural killer cell
immature T cell
hematopoietic precursor cell
DN1 thymic pro−T cell
T cell
large intestine goblet cell
mature natural killer cell
basophil
natural killer cell
immature NK T cell
Fraction A pre−pro B cell
mast cell
immature natural killer cell
granulocytopoietic cell
dendritic cell
professional antigen presenting cell
promonocyte
Langerhans cell
granulocyte monocyte progenitor cell
kidney cell
macrophage
granulocyte
monocyte
blood cell
non−classical monocyte
leukocyte
myeloid cell
classical monocyte
Kupffer cell
alveolar macrophage